



DR. RAJESH K. SHARMA  
HOSPITAL & CLINICAL  
DEPARTMENT OF  
GYN & OBSTETRICS

**TOMB**

Original model  
Fetal membranes  
Fetal membranes  
Fetal membranes  
Fetal membranes

**FETAL LUNG**  
Large white lobes  
and a smaller lobe  
at the base of the  
lung. It is the  
lung of the fetus.  
It is the lung of  
the fetus.

Small  
artery

DR. RAJESH K. SHARMA  
HOSPITAL & CLINICAL  
DEPARTMENT OF  
GYN & OBSTETRICS

**PORTAL VEIN  
PANCREAS & SPLEEN**

DR. RAJESH K. SHARMA  
HOSPITAL & CLINICAL  
DEPARTMENT OF  
GYN & OBSTETRICS

**PRENATAL CULTURE**

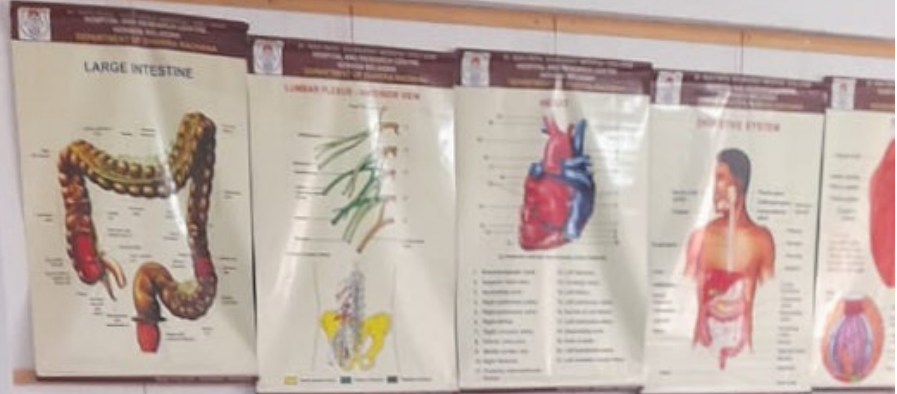DR. RAJESH K. SHARMA  
HOSPITAL & CLINICAL  
DEPARTMENT OF  
GYN & OBSTETRICS

**PLACENTA**  
The placenta is the  
organ that develops  
in the uterus during  
pregnancy. It is the  
organ that provides  
nutrients to the fetus.  
It is the organ that  
provides nutrients to  
the fetus.

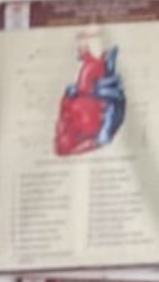
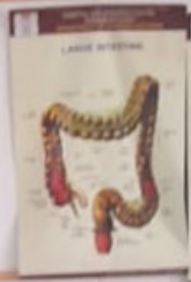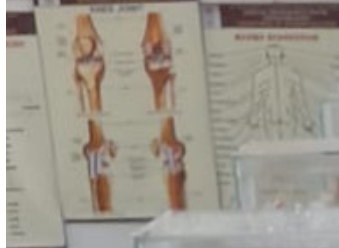**CORD**  
The umbilical cord  
is the organ that  
connects the fetus to  
the placenta. It is  
the organ that  
provides nutrients to  
the fetus.

MOUTH SIDE DEVELOPMENT OF PARTS

MOUTH SIDE DEVELOPMENT OF PARTS













SKULL BONES

CLAVICLE

SCAPULA

VERTEBRAE

SACRUM

RADIUS

ULNA

FIBULA

TARSALS



















